

SEARCH



Advanced Search

Log In

ABOUT US

NEWS & PUBLICATIONS

MEMBERS

CME CENTER

CLINICAL & RESEARCH

PRACTICE MGMT

POLICY & ADVOCACY

CAREERS

[AAFP Home Page](#) > [News & Publications](#) > [Journals](#) > [American Family Physician®](#) > [Vol. 74/No. 4 \(August 15, 2006\)](#)

American Family Physician®

A peer reviewed journal of the American Academy of Family Physicians

[AFP HOME](#) | [LATEST ISSUE](#) | [PAST ISSUES](#) | [CME QUIZ](#) | [CONTACT AFP](#) | [SEARCH AFP](#)August 15, 2006 ([table of contents](#))

Vol. 74 No. 4

[Email This Link](#) [Search AFP](#) [Browse by Topic](#)**► MEDLINE:**

- [Citation](#)
- [Related Articles](#)

► MORE BY:

- Nield LS
[AFP](#) [MEDLINE](#)
- Mahajan P
[AFP](#) [MEDLINE](#)
- Joshi A
[AFP](#) [MEDLINE](#)
- Kamat D
[AFP](#) [MEDLINE](#)

Rickets: Not a Disease of the Past

LINDA S. NIELD, M.D., *West Virginia University School of Medicine, Morgantown, West Virginia*PRASHANT MAHAJAN, M.D., M.P.H., *Wayne State University School of Medicine, Detroit, Michigan*APARNA JOSHI, M.D., *Children's Hospital of Michigan, Detroit, Michigan*DEEPAK KAMAT, M.D., PH.D., *Wayne State University School of Medicine, Detroit, Michigan*

Rickets develops when growing bones fail to mineralize. In most cases, the diagnosis is established with a thorough history and physical examination and confirmed by laboratory evaluation. Nutritional rickets can be caused by inadequate intake of nutrients (vitamin D in particular); however, it is not uncommon in dark-skinned children who have limited sun exposure and in infants who are breastfed exclusively. Vitamin D-dependent rickets, type I results from abnormalities in the gene coding for 25(OH)D₃-1-alpha-hydroxylase, and type II results from defective vitamin D receptors. The vitamin D-resistant types are familial hypophosphatemic rickets and hereditary hypophosphatemic rickets with hypercalciuria. Other causes of rickets include renal disease, medications, and malabsorption syndromes. Nutritional rickets is treated by replacing the deficient nutrient. Mothers who breastfeed exclusively need to be informed of the recommendation to give their infants vitamin D

supplements beginning in the first two months of life to prevent nutritional rickets. Vitamin D-dependent rickets, type I is treated with vitamin D; management of type II is more challenging. Familial

ACF

This article exemplifies the AAFP 2006 Annual Clinical Focus on caring for children and adolescents.

► **Patient information:** [A handout on rickets, written by the authors of this article, is provided on page 629.](#)

► **See related editorial on** [page 561.](#)



A PDF version of this document is available. [Download PDF now](#) (8 pages /303 KB).

hypophosphatemic rickets is treated with phosphorus and vitamin D, whereas hereditary hypophosphatemic rickets with hypercalciuria is treated with phosphorus alone. Families with inherited rickets may seek genetic counseling. The aim of early diagnosis and treatment is to resolve biochemical derangements and prevent complications such as severe deformities that may require surgical intervention. (Am Fam Physician 2006;74:619-26, 629-30. Copyright © 2006 American Academy of Family Physicians.)

Illustrative Case

The mother of a 26-month-old black infant expresses concern that her son is not growing properly. Born at 34 weeks of gestation at 3 lb, 5 oz (1.5 kg), he was exclusively breastfed until 11 months of age. He is a picky eater, is breastfed twice daily, and consumes minimal dairy products.

SORT: KEY RECOMMENDATIONS FOR PRACTICE		
<u>Clinical recommendation</u>	<u>Evidence rating</u>	<u>References</u>
Physicians should provide 200 IU of vitamin D per day to all breastfed and nonbreastfed infants who consume less than 500 mL of vitamin D-fortified formula per day and all children and adolescents who consume less than 500 mL of vitamin D-fortified milk per day, do not get regular sunlight exposure, and do not get 200 IU of vitamin D supplement per day from a multivitamin.	C	12, 20
Surgical intervention may be necessary to repair severe bony abnormalities in children with rickets, but it should not be undertaken until the biochemical derangements have resolved so that optimal healing occurs at the surgical site.	C	31
Vitamin D-deficiency rickets can be treated initially with high-dose vitamin D and calcium and phosphorus supplements.	C	35-37

A = consistent, good-quality patient-oriented evidence; B = inconsistent or limited-quality patient-oriented evidence; C = consensus, disease-oriented evidence, usual practice, expert opinion, or case series. For information about the SORT evidence rating system, see page 542 or <http://www.aafp.org/afpsort.xml>.

His examination reveals a weight of 21 lb (9.6 kg; below the fifth percentile for age), height of 72.5 cm (below the fifth percentile), and head circumference of 74.5 cm (50th percentile). Other abnormal findings include frontal bossing, open anterior fontanel, wide wrists, and bowlegs.

Nutritional rickets is suspected and confirmed with laboratory and radiographic evaluations. Levels of serum alkaline phosphatase and parathyroid hormone are elevated, and calcidiol (25[OH]D₃) is decreased. Radiographic images of the wrist show fraying and cupping of the distal radius and ulna, as well as bone demineralization. Treatment is initiated with oral solution of ergocalciferol at 4,000 IU per

day for six weeks with close monitoring of calcium and phosphorus levels.

Introduction

Rickets is not a disease only of the past, nor is it limited to developing countries. Until recently, vitamin D supplementation for breastfed infants was not advised.^{1,2} However, multiple case reports³⁻¹¹ of nutritional rickets in the United States have prompted the recent recommendation by the American Academy of Pediatrics to provide a daily vitamin D supplement for all solely breastfed babies beginning in the first two months of life.¹² In the United States, rickets should be included in the differential diagnosis of children presenting with failure to thrive, developmental delay, and orthopedic abnormalities. Early diagnosis is essential because morbidity can be minimized if children are treated before eight months of age.⁷ An extensive literature search of MEDLINE forms the basis of this report, which briefly addresses several causes of rickets with a more in-depth review of nutritional rickets.

Epidemiology

Because rickets is not a reportable disease in the United States, national data are unavailable. Statistics from Connecticut reveal that less than one third of children with rickets between 1986 and 2000 had nutritional deficiencies, whereas the remaining children had underlying disease or genetic factors responsible for the illness.³ Nutritional rickets is the main type reported outside the United States, followed by vitamin D-dependent, vitamin D-resistant, and renal rickets¹³ (*Table 1*^{4,14-20}).

TABLE 1

Various Types of Rickets with Clinical Features and Treatments

<i>Type</i>	<i>Causes</i>	<i>Inheritance pattern</i>	<i>Clinical features</i>	<i>Treatment*</i>
Nutritional rickets or vitamin D-deficiency rickets	Vitamin D deficiency, phosphorus or calcium deficiency (rare), inadequate sunlight exposure, secondary to malabsorption syndromes (IBD, celiac disease, cystic fibrosis)	NA	Skeletal findings, abnormal gait, hypocalcemic tetany/seizures, developmental delay, failure to thrive	Replace the deficient nutrient orally; may need to administer vitamin D intramuscularly if rickets secondary to malabsorption.

	[rarely])			
Vitamin D-dependent rickets				
Type I or pseudovitamin D-deficiency rickets	Deficiency of renal 25(OH) D ₃ -1-alpha-hydroxylase	Autosomal recessive	Younger than two years, hypocalcemic tetany, severe bony changes, seizures	Calcitriol (Rocaltrol)
Type II or hereditary 1-alpha, 25-dihydroxyvitamin D-resistant rickets	Defective interaction between calcitriol and receptor	Autosomal recessive	Younger than one year, severe bony changes, alopecia	Massive doses of calcitriol and calcium
Vitamin D-resistant rickets				
Familial hypophosphatemic rickets or X-linked hypophosphatemic rickets	Impaired proximal renal tubular reabsorption of phosphorus and inappropriately normal calcitriol levels	X-linked dominant	Short stature, leg bowing, dental abnormalities	Oral phosphate and calcitriol
Hereditary hypophosphatemic rickets with hypercalciuria	Impaired proximal renal tubular reabsorption of phosphorus and increased calcitriol	Autosomal recessive, autosomal dominant	Bone pain, muscular weakness	Oral phosphate
Miscellaneous				
Renal rickets or renal osteodystrophy	Loss of functional renal parenchyma caused by chronic renal failure leads to mineral derangements and decreased calcitriol production	NA	Bone pain, arthralgias, fractures, muscle weakness, failure to thrive	Vitamin D and phosphate-binding compound
Rickets of prematurity	Multifactorial	NA	Osteopenia, fractures	Replace dietary deficiencies and minimize iatrogenic causes.
Tumor-induced or oncogenic rickets	Tumor-induced inhibition of renal 25(OH)D ₃ -1-alpha-hydroxylase	NA	Fractures, bone pain, muscle weakness	Treat underlying malignancy.

IBD = inflammatory bowel disease; NA = not applicable; PTH = parathyroid hormone.

**-Must closely monitor serum calcium, phosphorus, and alkaline phosphatase levels; renal function; urine calcium levels; and radiographic results.*

Information from references 4, and 14 through 20.

Unlike developing countries, the United States saw the eradication of nutritional rickets in the 1930s following the discovery that vitamin D possessed antirachitic properties.²¹ Today, in the absence of ongoing national surveillance, it is difficult to know how likely it is that a child with rickets will present to the primary care physician's office. As a result, the true burden of this condition must be estimated. In one study,²² the prevalence of nutritional rickets was estimated to be nine cases per 1 million children, whereas the Centers for Disease Control and Prevention places this rate at five cases per 1 million children six months to five years of age.²³ Of note, in multiple studies, most affected children were black.²²

TABLE 2

Skeletal and Radiographic Findings Associated with Rickets

Bowing or widening of physis	Flaring of wrists
Costochondral beading (rachitic rosary)	Fractures
Craniotabes	Fraying and cupping of metaphysis
Delayed closure of anterior fontanel	Frontal bossing of skull
Dental abnormalities	Genu valgum or varum
Flaring of ribs at diaphragm level (Harrison's groove)	Lordosis/kyphosis/scoliosis
	Osteopenia

Information from references 14, 19, and 24.

Pathogenesis

A disease that occurs during childhood, rickets is the failure of growing bone to mineralize. Many skeletal and radiographic changes can occur (*Table 2*^{14,19,24}) because of the lack of calcified osteoid and the buildup of unossified cartilage.¹⁴ Proper bone formation requires a complex interplay of several organs and chemicals (*Table 3*),²⁵ and vitamin D deserves special mention because any disturbance in its production, absorption, or metabolism is paramount in the development of rickets. Human beings maintain adequate levels of vitamin D by producing it from cholesterol or by absorbing it from ingested food sources. Sunlight is a vital component necessary for the production of vitamin D, which begins in the skin and ends in the kidney, as depicted in *Figure 1*.²⁵

Pathway of Vitamin D Production

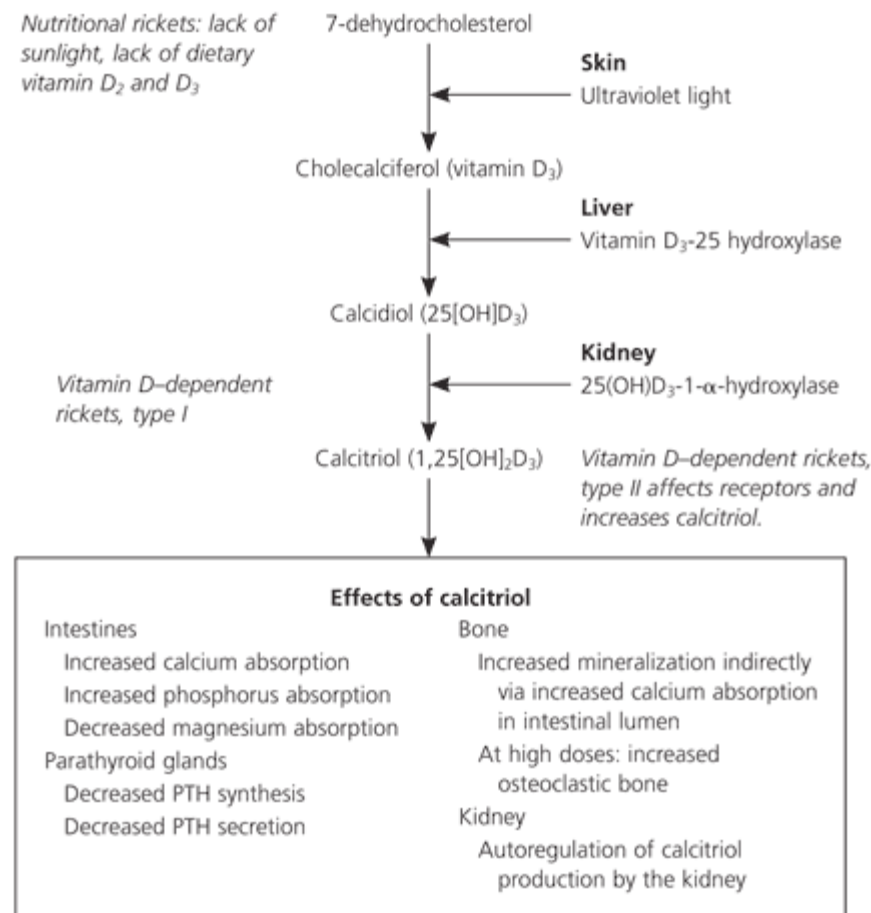


Figure 1. Simplified schematic pathway of vitamin D production. In skin, vitamin D production begins with conversion of 7-dehydrocholesterol to vitamin D₃ because of ultraviolet light. Another source of vitamin D is dietary intake of vitamins D₂ and D₃. Vitamin D₃ is converted in the liver to 25(OH)D₃ or calcidiol, the major circulating form of vitamin D. The enzyme 25(OH)D₃-1-alpha-hydroxylase in the kidney converts calcidiol to 1,25(OH)₂D₃ or calcitriol, the most active form of vitamin D. (PTH = parathyroid hormone.)

Information from reference 25.

Types of Rickets

NUTRITIONAL

Nutritional rickets results from inadequate sunlight exposure or inadequate intake of dietary vitamin D, calcium, or phosphorus. Although uncommon in the United States, vitamin D deficiency still can occur, particularly when an infant is solely breastfed, is dark skinned, or has limited sunlight exposure. Dark-skinned persons require more sunlight exposure than others to produce the same amount of vitamin D because melanin acts as a neutral filter and absorbs solar radiation.⁸ A diet deficient in calcium,³ such as one dependent on nonfortified milk substitutes, can lead to rickets.^{6,10,23} Nutritional rickets presents in the first two years of life with short stature, gait abnormality, developmental delay, and characteristic findings (*Tables 1*^{4,14-20} and *2*^{14,19,24}). Commonly, infants younger than six months present with hypocalcemic tetany or seizures, whereas older children present with failure to thrive or skeletal deformities.¹⁴

TABLE 3

Functions of Chemicals Involved in Bone Formation

<i>Chemical</i>	<i>Function</i>
Alkaline phosphatase	Exact function unknown; isoenzyme is elevated in conditions such as rickets that are associated with high bone turnover
Calcitonin	Bone: inhibits resorption Intestine: inhibits calcium and phosphorus absorption Kidney: increases calcium excretion, inhibits production of calcitriol
Calcitriol	Bone: indirectly stimulates bone synthesis via increased calcium absorption in intestinal lumen Intestine: increases calcium, phosphorus, and magnesium absorption Kidney: autoregulation of calcitriol production by the kidney Parathyroid gland: negative feedback to decrease secretion of parathyroid hormone
Parathyroid hormone	Bone: mobilizes calcium and phosphorus Intestine: indirectly increases calcium and phosphorus absorption by increasing calcitriol Kidney: increases calcitriol, increases calcium reabsorption, decreases phosphorus reabsorption

Information from reference 25.

VITAMIN D DEPENDENT

Vitamin D-dependent rickets, type I is secondary to a defect in the gene that codes for the production of renal 25(OH)D₃-1-alpha-hydroxylase (*Figure 1*²⁵). Vitamin D-dependent rickets, type II is a rare

autosomal disorder caused by mutations in the vitamin D receptor. Type II does not respond to vitamin D treatment; elevated levels of circulating calcitriol differentiate this type from type I.

VITAMIN D RESISTANT

Rickets refractory to vitamin D treatment may be caused by the most common heritable form, known as vitamin D-resistant rickets or familial hypophosphatemic rickets.^{15,16} Because of mutations of the phosphate-regulating gene on the X chromosome, renal wasting of phosphorus at the proximal tubule level results in hypophosphatemia.¹⁷ Normal levels of calcitriol are found in this disorder.

Hypophosphatemia also can occur secondary to hereditary hypophosphatemic rickets with hypercalciuria, which is believed to result from an isolated defect in renal reabsorption of phosphorus.

OTHER CAUSES

Various medical conditions and medications can cause rickets (*Table 4*).^{17,26,27} In rickets secondary to malignancy, the most common pathophysiology is tumor secretion of a renal phosphate-wasting factor and impaired calcitriol production.¹⁷ Rickets caused by renal disease (renal osteodystrophy) is caused by disturbances in calcium and phosphorus regulation and calcitriol production. Malabsorption syndromes such as celiac disease and cystic fibrosis can cause vitamin D deficiency.

TABLE 4

Conditions That Can Cause Rickets

Medications	Diseases of organs associated with vitamin D and calcium metabolism
Antacids	Kidney disease
Anticonvulsants	Liver and biliary tract disease
Corticosteroids	Malabsorption syndromes
Loop diuretics	Celiac disease
Malignancy	Cystic fibrosis (rare)
Prematurity	

Information from references 17, 26, and 27.

Premature infants are at risk of developing rickets from calcium and phosphorus deficiency and side effects of their medications (e.g., loop diuretics, corticosteroids). Other medications associated with the development of rickets include anticonvulsants and antacids. Phenytoin (Dilantin) may cause target organ resistance to calcitriol.²⁶ Excess oral administration of aluminum-containing antacids can lead to hypophosphatemic rickets caused by the phosphate-binding property of aluminum.²⁷

Evaluation

MEDICAL HISTORY

The infant's gestational age, diet, and degree of sunlight exposure should be noted. A detailed dietary history should include specifics of vitamin D and calcium intake. Researchers have suggested an appropriate amount of sunlight exposure for infants (i.e., 30 minutes per week if only in a diaper and two hours per week if fully clothed),²⁸ but the exact amount needed for a particular child is not known. It helps to know if the child avoids sun exposure completely. A family history of short stature, orthopedic abnormalities, poor dentition, alopecia, and parental consanguinity may signify inherited rickets.

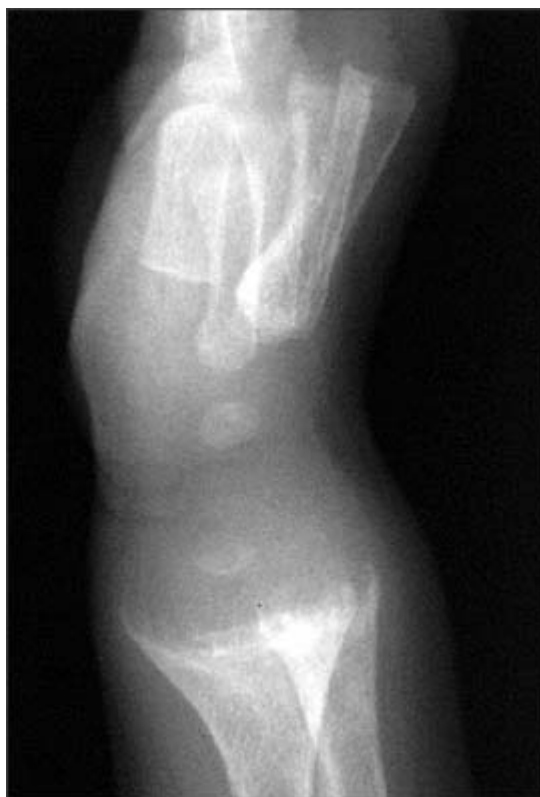

Figure 2. Radiographic image showing typical changes of rickets at the wrist. The distal ends of the radius and ulna display extensive cupping, fraying, and splaying of the diaphysis, with

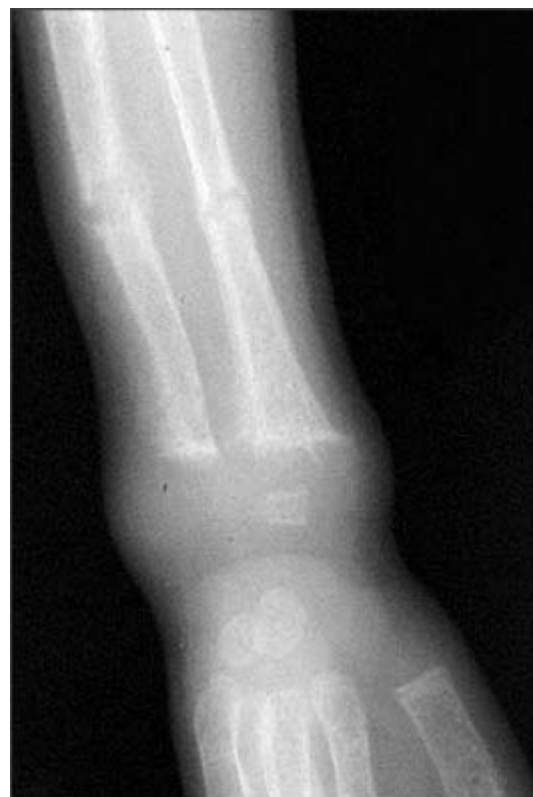

Figure 3. Radiographic image of wrist and forearm showing pathologic fractures of radius and ulna with rachitic changes of distal end of radius and ulna.

widening of the metaphysis.

The review of systems should focus on growth and orthopedic concerns and signs and symptoms of hypocalcemia, such as muscle cramps, numbness, paresthesias, tetany, and seizures.

PHYSICAL EXAMINATION

In children with rickets, complete physical and dental examinations should be performed. The entire skeletal system must be palpated to search for tenderness and bony abnormalities (*Table 2*^{14,19,24}).

Bowlegs in the absence of other findings are relatively common in normal children in the first two years of life; rickets should be suspected in older bowlegged children and in cases associated with asymmetry, pain, or progression in severity. Gait disturbances in the ambulatory child and neurologic abnormalities (such as hyperreflexia) in all children should be sought.

LABORATORY AND RADIOGRAPHIC FINDINGS

Laboratory investigation may include serum levels of calcium (total and ionized with serum albumin), phosphorus, alkaline phosphatase, parathyroid hormone, urea nitrogen, creatinine, and calcidiol. Urine studies include urinalysis and levels of urinary calcium and phosphorus. The serum level of calcidiol is indicative of the patient's overall vitamin D status.²⁹ Although calcitriol is the active form of vitamin D, it has a short half-life and circulates at a concentration that is 1,000 to 2,000 times less than calcidiol.²⁹ Depending on the stage of the disease, laboratory values can vary. The most common laboratory findings in nutritional rickets are decreases in serum calcium, serum phosphorus, calcidiol, calcitriol, and urinary calcium. Conversely, parathyroid hormone, alkaline phosphatase, and urinary phosphorus levels are elevated.

An anteroposterior radiograph of rapidly growing skeletal areas, such as the knee or wrist, is most helpful in diagnosing rickets. The skeletal changes caused by rickets usually are most pronounced at the knees, wrists, and anterior rib ends (rachitic rosary)²⁴ (*Figures 2 through 4*). Classic radiographic findings include widening of the distal physis,

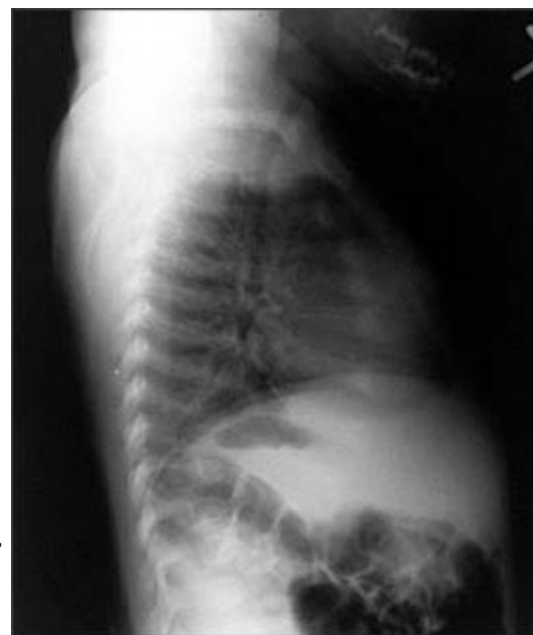

Figure 4. Chest radiograph revealing rachitic rosary (i.e., enlargement of ribs at the costochondral junction).

fraying and widening of the metaphysis, and angular deformities of the arm and leg bones. Bony changes of rickets may be mistaken for other conditions of childhood such as congenital syphilis, osteogenesis imperfecta, or child abuse,³⁰ and it can be beneficial to consult an experienced children's radiologist for radiographic interpretation.

Treatment

Surgical intervention may be necessary to repair severe bony abnormalities, but for optimal healing to occur, the metabolic and nutritional imbalances have to be corrected first.³¹ Vitamin D and supplements of calcium and phosphorus are used to treat nutritional rickets.

Various vitamin D preparations, dosages (high versus low), dosing schedules (single versus multiple doses), and administration routes (oral or intramuscular) are available (*Table 5*).^{32,33} Ergocalciferol (Calciferol) is a useful medication for infants and children because it can be administered intramuscularly or orally in liquid or capsule form. The capsules can be softened in water and mixed with a palatable food such as applesauce.³⁴ A single intramuscular or oral dose of various strengths (150,000 to 600,000 IU) of vitamin D in patients as young as three months has been studied and found to be adequate treatment for nutritional rickets.³⁵⁻³⁷ Hypercalcemia is more likely with oral doses greater than 300,000 IU.³⁵

TABLE 5

Vitamin D Preparations for Use in Children with Rickets

The rightsholder did not grant rights to reproduce this item in electronic media. For the missing item, see the original print version of this publication.

Researchers comparing a single intramuscular dose (600,000 IU) of vitamin D to a lower daily oral dosage (2,000 IU) for four weeks found that patients who received the intramuscular dose responded promptly without hypervitaminosis, whereas 40 percent of infants who received the oral dosages had no or minimal response.³⁸ The physician must determine the best treatment strategy for each patient on a case-by-case basis. For example, if compliance is a major concern, the single intramuscular dose may be more appropriate.

After treatment initiation, all patients will require careful monitoring of serum calcium, phosphorus, alkaline phosphatase, and calcidiol levels and of urine calcium and phosphorus levels. A spot urine calcium to creatinine ratio should be followed to detect hypercalciuria. Adjustments to medications are made to accommodate any abnormal fluctuations in serum or urine values. The earliest biochemical

change after treatment initiation is a rise in the level of phosphorus followed by calcium within the first week. Radiographic changes may be evident within a week, and physical examination findings may normalize within six months. No matter which treatment course is chosen, the physician has to closely monitor the child's progress.

With regard to nutritional rickets, the most important role of the primary care physician is helping parents prevent it. Along with sun protection advice, measures needed to prevent nutritional rickets must be stressed to the child's caregivers. Besides all exclusively breastfed infants, some older children also may need vitamin D supplementation. Parents should be encouraged to give their children foods that are high in calcium (*Table 6*³³).

TABLE 6

Calcium Content of Various Foods

<i>Food (approximate serving)</i>	<i>Amount of calcium (approximate mg)</i>
Breast milk (16 oz)	125
Formula, cow's milk-based (16 oz)	265
Dairy products	
Cheddar cheese (1 oz)	200
Cow's milk (1 cup)	250
Ice cream (1 cup)	150
Yogurt (4 oz)	150
Fast foods	
Cheeseburger	20
Chicken nuggets (four to six pieces)	13
French fries (small order)	10
Pizza (one slice)	145
Greens	
Collard greens (1/2 cup, cooked)	150
Spinach (1 cup, cooked)	150

Information from reference 33.

Because vitamin D-dependent rickets, type I is caused by lack of production of calcitriol, treatment requires the replacement of that active product. The treatment of type II is more complex,³⁹ and consultation with a children's nephrologist is advised.

Familial hypophosphatemic rickets is treated with oral phosphorus and calcitriol (Rocaltrol), whereas hereditary hypophosphatemic rickets with hypercalciuria requires replacement of oral phosphorus alone. Investigators stress that treatment begun early in life lessens the disease burden.⁴⁰ To ensure early treatment, infants of affected parents must be screened often for hypophosphatemia and increased levels of serum alkaline phosphatase.

The Authors

LINDA S. NIELD, M.D., is associate professor of pediatrics at West Virginia University (WVU) School of Medicine, Morgantown. She received her medical degree from Dartmouth Medical School, Hanover, N.H., and completed a residency in pediatrics at WVU Children's Hospital, Morgantown.

PRASHANT MAHAJAN, M.D., M.P.H., is a staff pediatrician in pediatric emergency medicine at Children's Hospital of Michigan, Detroit, and associate professor of pediatrics at Wayne State University School of Medicine, Detroit. He received his medical degree from Bombay University, India, and completed a residency in pediatrics and a fellowship in pediatric emergency medicine at Children's Hospital of Michigan. Dr. Mahajan also received a master's in public health degree in health management and policy from the University of Michigan School of Public Health, Ann Arbor.

APARNA JOSHI, M.D., is assistant professor of pediatric imaging at Children's Hospital of Michigan. She received her medical degree from Northwestern University, Chicago, Ill., and completed a residency in radiology and a fellowship in pediatric radiology from Columbia-Presbyterian Medical Center, New York, N.Y.

DEEPAK KAMAT, M.D., PH.D., is professor of pediatrics at Wayne State University School of Medicine and is an attending pediatrician for the Department of Pediatrics at Children's Hospital of Michigan. He received his medical degree from Bombay University and completed a residency and fellowship at the University of Minnesota, Minneapolis.

Address correspondence to Deepak Kamat, M.D., Ph.D., Children's Hospital of Michigan, 3901 Beaubien Blvd., Detroit, MI 48201 (e-mail: dkamat@med.wayne.edu). Reprints are not available from the authors.

Author disclosure: Nothing to disclose.

REFERENCES

1. Supplementation for breast-fed and bottle fed infants. Vitamin supplements. In: Shelov SP, ed. *Caring for Your Baby and Young Child: Birth to Age 5*. New York, N.Y.: Bantam Books, 1991:104-5.
2. Wharton B. Weaning: pathophysiology, practice and policy. In: Walker WA, Watkins JB, eds. *Nutrition in Pediatrics: Basic Science and Clinical Applications*. 2nd ed. Hamilton, Ontario: B.C. Decker, 1997:433.
3. DeLucia MC, Mitnick ME, Carpenter TO. Nutritional rickets with normal circulating 25-hydroxyvitamin D: a call for reexamining the role of dietary calcium intake in North American infants. *J Clin Endocrinol Metab* 2003;88:3539-45.
4. Peng LF, Serwint JR. A comparison of breastfed children with nutritional rickets who present during and after the first year of life. *Clin Pediatr* 2003;42:711-7.
5. Biser-Rohrbaugh A, Hadley-Miller N. Vitamin D deficiency in breast-fed toddlers. *J Pediatr Orthop* 2001;21:508-11.

6. Carvalho NF, Kenney RD, Carrington PH, Hall DE. Severe nutritional deficiencies in toddlers resulting from health food milk alternatives. *Pediatrics* 2001;107:E46.
7. Tomashek KM, Nesby S, Scanlon KS, Cogswell ME, Powell KE, Parashar UD, et al. Nutritional rickets in Georgia. *Pediatrics* 2001;107:E45.
8. Kreiter SR, Schwartz RP, Kirkman HN Jr, Charlton PA, Calikoglu AS, Davenport ML. Nutritional rickets in African American breast-fed infants. *J Pediatr* 2000;137:153-7.
9. Fitzpatrick S, Sheard NF, Clark NG, Ritter ML. Vitamin D-deficient rickets: a multifactorial disease. *Nutr Rev* 2000;58:218-22.
10. Shah M, Salhab N, Patterson D, Seikaly MG. Nutritional rickets still afflict children in north Texas. *Tex Med* 2000;96:64-8.
11. Weisberg P, Scanlon KS, Li R, Cogswell ME. Nutritional rickets among children in the United States: review of cases reported between 1986 and 2003. *Am J Clin Nutr* 2004;80(6 suppl):1697S-705S.
12. Gartner LM, Greer FR, for the Section on Breastfeeding and Committee on Nutrition. American Academy of Pediatrics. Prevention of rickets and vitamin D deficiency: new guidelines for vitamin D intake. *Pediatrics* 2003;111(4 pt 1):908-10.
13. Abdullah MA, Salhi HS, Bakry LA, Okamoto E, Abomelha AM, Stevens B, et al. Adolescent rickets in Saudi Arabia: a rich and sunny country. *J Pediatr Endocrinol Metab* 2002;15:1017-25.
14. Tolo VT, Wood BP. Torsional and angular conditions in the lower extremity. In: Tolo VT, Wood BP, eds. *Pediatric Orthopaedics in Primary Care*. Baltimore, Md.: Williams & Wilkins, 1993:258-60.
15. Chung WT, Niu DM, Lin CY. Clinical aspects of X-linked hypophosphatemic rickets. *Acta Paediatr Taiwan* 2002;43:26-34.
16. Seikaly MG, Baum M. Thiazide diuretics arrest the progression of nephrocalcinosis in children with X-linked hypophosphatemia. *Pediatrics* 2001;108:E6.
17. Brame LA, White KE, Econs MJ. Renal phosphate wasting disorders: clinical features and pathogenesis. *Semin Nephrol* 2004;24:39-47.
18. Al-Khenaizan S, Vitale P. Vitamin D-dependent rickets type II with alopecia: two case reports and review of the literature. *Int J Dermatol* 2003;42:682-5.
19. McWhorter AG, Seale NS. Prevalence of dental abscess in a population of children with vitamin D-resistant rickets. *Pediatr Dent* 1991;13:91-6.
20. Chaussain-Miller C, Sinding C, Wolikow M, Lasfargues JJ, Godeau G, Garabedian M. Dental abnormalities in patients with familial hypophosphatemic vitamin D-resistant rickets: prevention by early treatment with 1-hydroxyvitamin D. *J Pediatr* 2003;142:324-31.
21. Rajakumar K. Vitamin D, cod-liver oil, sunlight and rickets: a historical perspective. *Pediatrics* 2003;112:E132-5.
22. Scanlon KS, ed. Vitamin D expert panel meeting: October 11-12, 2001, Atlanta, Ga. Final report. Accessed April 20, 2006, at: http://www.cdc.gov/nccdphp/dnpa/nutrition/pdf/Vitamin_D_Expert_Panel_Meeting.pdf.
23. Centers for Disease Control and Prevention. Severe malnutrition among young children-Georgia, January 1997-June 1999. *MMWR Morb Mortal Wkly Rep* 2001;50:224-7.
24. Markowitz RI, Zackai E. A pragmatic approach to the radiologic diagnosis of pediatric syndromes and skeletal dysplasias. *Radiol Clin North Am* 2001;39:791-802.
25. Drezner MK. Rickets and osteomalacia. In: Goldman L, Ausiello DA, eds. *Cecil Textbook of Medicine*. 22nd ed. Philadelphia, Pa.: Saunders, 2004:1545.
26. Bringhurst FR, Demay MD, Kronenberg HM. Hormones and disorders of mineral metabolism. In:

- Larsen PR, Kronenberg HM, Melmed S, Polonsky KS, eds. Williams Textbook of Endocrinology. 10th ed. Philadelphia, Pa.: Saunders, 2003:1346.
27. Robinson RF, Casavant MJ, Nahata MC, Mahan JD. Metabolic bone disease after chronic antacid administration in an infant. *Ann Pharmacother* 2004;38:265-8.
 28. Specker BL, Valanis B, Hertzberg V, Edwards N, Tsang RC. Sunshine exposure and serum 25-hydroxyvitamin D concentrations in exclusively breast-fed infants. *J Pediatr* 1985;107:372-6.
 29. Greer FR. Vitamin D deficiency-it's more than rickets. *J Pediatr* 2003;143:422-3.
 30. DeRusso PA, Spevak MR, Schwarz KB. Fractures in biliary atresia misinterpreted as child abuse. *Pediatrics* 2003;112(1 pt 1):185-8.
 31. Calmar EA, Vinci RJ. The anatomy and physiology of bone fracture and healing. *Clin Ped Emerg Med* 2002;3:85-93.
 32. Khatib R, Alsaek Y, Cakan N, Kamat DM. Nutritional rickets. A case report and review. *Consultant Pediatrician* 2005;4:33-9.
 33. National Institutes of Health Consensus Conference. Optimal calcium intake. NIH Consensus Development Panel on Optimal Calcium Intake. *JAMA* 1994;272:1942-8.
 34. Pal BR, Shaw NJ. Rickets resurgence in the United Kingdom: improving antenatal management in Asians [Published reply appears in *J Pediatr* 2001;139:338]. *J Pediatr* 2001;139:337-8.
 35. Cesur Y, Caksen H, Gundem A, Kirimi E, Odabas D. Comparison of low and high dose vitamin D treatment in nutritional vitamin D deficiency rickets. *J Pediatr Endocrinol Metab* 2003;16:1105-9.
 36. Kutluk G, Cetinkaya F, Basak M. Comparisons of oral calcium, high dose vitamin D and a combination of these in the treatment of nutritional rickets in children. *J Trop Pediatr* 2002;48:351-3.
 37. Shah BR, Finberg L. Single-day therapy for nutritional vitamin D-deficiency rickets: a preferred method. *J Pediatr* 1994;125:487-90.
 38. Lubani MM, al-Shab TS, al-Saleh QA, Sharda DC, Quattawi SA, Ahmed SA, et al. Vitamin-D-deficiency rickets in Kuwait: the prevalence of a preventable disease. *Ann Trop Paediatr* 1989;9:134-9.
 39. Wong GW, Leung SS, Law WY, Cheung NK, Oppenheimer SJ. Oral calcium treatment in vitamin D-dependent rickets type II. *J Paediatr Child Health* 1994;30:444-6.
 40. Makitie O, Doria A, Kooh SW, Cole WG, Daneman A, Sochett E. Early treatment improves growth and biochemical and radiographic outcome in X-linked hypophosphatemic rickets. *J Clin Endocrinol Metab* 2003;88:3591-7.

Copyright © 2006 by the American Academy of Family Physicians.

This content is owned by the AAFP. A person viewing it online may make one printout of the material and may use that printout only for his or her personal, non-commercial reference. This material may not otherwise be downloaded, copied, printed, stored, transmitted or reproduced in any medium, whether now known or later invented, except as authorized in writing by the AAFP. Contact afpserv@aafp.org for copyright questions and/or permission requests.

[August 15, 2006 Table of Contents](#)
[AFP Home](#) | [Latest Issue](#) | [Past Issues](#) | [CME Quiz](#) | [Contact AFP](#) | [Search AFP](#)

